

**BOARD OF MEDICOLEGAL INVESTIGATIONS
OFFICE OF THE CHIEF MEDICAL EXAMINER**

OFFICE USE ONLY

Central Office
901 N. Stonewall
Oklahoma City, Oklahoma 73117
(405) 239-7141 Fax (405) 239-2430

Eastern Division
1115 West 17th
Tulsa, Oklahoma 74107
(918) 582-0985 Fax (918) 585-1549

Re _____ Co _____

I hereby certify that this is a true and correct copy of the original document. Valid only when copy bears imprint of the office seal.

By _____

Date _____

REPORT OF INVESTIGATION BY MEDICAL EXAMINER

| | | | | |
|--|-----------|------------------------|---------------|----------|
| DECEDENT First-Middle-Last Names (Please avoid use of initials) TAYLOR DAWN PASCHAL | Age 13 | Birth Date 4/6/1995 | Race WHITE | Sex F |
|--|-----------|------------------------|---------------|----------|

HOME ADDRESS - No. - Street, City, State
RT 1, WELEETKA, OK

| | | |
|--|------------------|---------------|
| EXAMINER NOTIFIED BY - NAME - TITLE (AGENCY, INSTITUTION, OR ADDRESS) BEN ROSSER @ OSBI | DATE 6/8/2008 | TIME 19:47 |
|--|------------------|---------------|

| | | | | | |
|---|-----------------------|--------------------|-------------------------------|------------------|------------------------|
| INJURED OR BECAME ILL AT (ADDRESS) 1.1 MI. NORTH OF COLEMAN RD. ON COUNTY RD. 5424 | CITY WELEETKA | COUNTY OKFUSKEE | TYPE OF PREMISES DIRT ROAD | DATE 6/8/2008 | TIME Unknown |
| LOCATION OF DEATH 1.1 NORTH OF COLEMAN RD. ON COUNTY RD.5424 | CITY WELEETKA | COUNTY OKFUSKEE | TYPE OF PREMISES DIRT ROAD | DATE 6/8/2008 | TIME 17:21 FOUND |
| BODY VIEWED BY MEDICAL EXAMINER 901 NORTH STONEWALL | CITY OKLAHOMA CITY | COUNTY OKLAHOMA | TYPE OF PREMISES MORGUE | DATE 6/9/2008 | TIME 14:30 |

IF MOTOR VEHICLE ACCIDENT: DRIVER PASSENGER PEDESTRIAN

TYPE OF VEHICLE: AUTOMOBILE LIGHT TRUCK HEAVY TRUCK BICYCLE MOTORCYCLE OTHER: _____


| DESCRIPTION OF BODY | RIGOR | LIVOR | EXTERNAL OBSERVATION | | NOSE | MOUTH | EARS |
|-------------------------------|---|--|---|--|--------------------------|--------------------------|--------------------------|
| | | | | | BLOOD | OTHER | |
| EXTERNAL PHYSICAL EXAMINATION | Jaw <input type="checkbox"/> Complete <input type="checkbox"/> Neck <input type="checkbox"/> Absent <input type="checkbox"/> Arms <input type="checkbox"/> Passing <input type="checkbox"/> Legs <input type="checkbox"/> Passed <input type="checkbox"/> Decomposed <input type="checkbox"/> | Color _____ Lateral <input type="checkbox"/> Posterior <input type="checkbox"/> Anterior <input type="checkbox"/> Regional _____ | Beard _____ Hair _____ Eyes: Color _____ Mustache _____ Opacities _____ Pupils: R _____ L _____ Body Length _____ Body Weight _____ | | <input type="checkbox"/> | <input type="checkbox"/> | <input type="checkbox"/> |
| | | | | | <input type="checkbox"/> | <input type="checkbox"/> | <input type="checkbox"/> |

Significant observations and injury documentations - (Please use space below)
SEE AUTOPSY PROTOCOL

Probable Cause of Death:
MUTIPLE GUNSHOT WOUNDS

Other Significant Medical Conditions:

| | |
|---|--|
| Manner of Death: Natural <input type="checkbox"/> Accident <input type="checkbox"/> Suicide <input type="checkbox"/> Homicide <input checked="" type="checkbox"/> Unknown <input type="checkbox"/> Pending <input type="checkbox"/> | Case disposition: Autopsy Yes <input checked="" type="checkbox"/> No <input type="checkbox"/> Authorized by <u>MEDICAL EXAMINER</u> Pathologist <u>CHAI S. CHOI M.D.</u> Not a medical examiner case <input type="checkbox"/> |
|---|--|

| | | |
|---|---|-------------------------|
| MEDICAL EXAMINER: Name, Address and Telephone No. CHAI S. CHOI M.D. 901 N. STONEWALL OKLAHOMA CITY, OK 73117 | I hereby state that, after receiving notice of the death described herein, I conducted an investigation as to the cause and manner of death, as required by law, and that the facts contained herein regarding such death are true and correct to the best of my knowledge.  _____ Signature of Medical Examiner CHAI S. CHOI M.D. Computer generated report 0802189 | _____ Date 6/10/2008 |
|---|---|-------------------------|



Board of Medicolegal Investigations
Office of the Chief Medical Examiner
 901 N. Stonewall
 Oklahoma City, Oklahoma 73117
 (405) 239-7141 Voice
 (405) 239-2430 Fax

CERTIFICATION
 I hereby certify that this document is a true and correct copy of the original document. Valid only when copy bears imprint of the office seal.
 By _____
 Date _____

REPORT OF AUTOPSY

| | | | | | | |
|--|------------------|---------------------------------|-------------------|-----------------|-----------------------------|---------------------------|
| Decedent TAYLOR DAWN PASCHAL | Age 13 | Birth Date 04/06/1995 | Race WH | Sex F | Autopsy No 443-08 | Case No 0802189 |
|--|------------------|---------------------------------|-------------------|-----------------|-----------------------------|---------------------------|

| | | | |
|---|--------------|-------------------------|--|
| Type of Death Violent, unusual or unnatural | Means | ID By Toe tag | Authority for Autopsy CHAI S. CHOI, M.D. |
|---|--------------|-------------------------|--|

Present at Autopsy
 Jason Snider

PATHOLOGICAL DIAGNOSIS

- I. Entrance gunshot wound, left upper lip, penetrating through base of the tongue, orbital bone, right orbital lobe, right caudate nucleus including basal ganglia, right parietal lobe.
 - a. Entrance gunshot wound: no soot blackening or powder stippling.
 - b. No exit gunshot wound present; a markedly damaged copper coated lead bullet, small in size recovered.
 - c. Direction: backward, upward slightly toward the right.
 - d. Brain with contusive laceration and subarachnoid hemorrhages (basal cisterns).
- II. Entrance gunshot wound, left submentum, fracturing regional mandible and base of the skull.
 - a. Entrance gunshot wound: fine powder grain (approximately 8 x 10 cm), with powder stippling (3 x 11 cm).
 - b. No exit gunshot wound present: markedly damaged copper coated lead bullet, small in size and piece of lead recovered.
 - c. Direction: backward and slightly toward the right.
 - d. Subdural hemorrhages of cervical spinal cord (C3) with periosteal contusion.
- III. Entrance gunshot wound, right cheek, perforating through soft fibrofatty musculature to the back of the neck.
 - a. Entrance gunshot wound: no soot or powder stippling; oval shaped contusive rim.
 - b. Exit gunshot wound present; no bullet recovered.
 - c. Direction: backward, downward to the left.

Continued on Page 2

CAUSE OF DEATH: MULTIPLE GUNSHOT WOUNDS

The facts stated herein are true and correct to the best of my knowledge and belief.

Chai S. Choi, M.D.

OCME Central Division

06/09/2008 2:30 PM

CHAI S. CHOI, M.D.

Pathologist

Location of Autopsy

Date and Time of Autopsy

PATHOLOGICAL DIAGNOSIS
(Continued)

AUTOPSY NO. ML 443-08

CASE NO. 0802189

- IV. Entrance gunshot wound, left groin, penetrating through the left peritoneal muscle, descending colon (x1), small intestine (x2), stomach, left hemisphere of the diaphragm, lower lobe of the left lung, perivertebral region (thoracic spine #5) to the left back.
- a. Entrance gunshot wound: no soot blackening or powder stippling.
 - b. Partial exit gunshot wound with copper jacketed bullet, medium in size, in situ.
 - c. Direction: backward, upward slightly toward the right.
 - d. Left hemothorax (approximately 500 mL of blood) with partial collapse, right hemothorax (approximately 50 mL) and hemoperitoneum (approximately 150 mL).
- V. Entrance gunshot wound, right hand (third knuckle), perforating right third finger with compound fractures and multiple lacerations.
- a. Entrance gunshot wound: no soot blackening or powder stippling.
 - b. Exit gunshot wound with multiple lacerations.
 - c. Direction: forward and downward.
- VI. Multiple cutaneous abrasions and contusions over the right upper cheek, left knee, left ankle, and back of the left arm.

Comment: The decedent is a 13 year old white female child who was shot multiple times. The decedent was found in sandy dirt ditch located on the west side of the roadway. There was a large purse over her left shoulder.

Complete autopsy showed five separate gunshot wounds; two over the left side of the face, one over the right side of the face, one in the left groin, and one at the third right knuckle. The two gunshot wounds of the left side of the face are individually potentially fatal. The gunshot wound of the right cheek may not be fatal with prompt medical intervention. The gunshot wound over the left groin is potentially fatal. There is entrance gunshot wound perforating the right third knuckle and finger with compound fracture. Two damaged copper coated lead bullets, small in size and one medium size copper jacketed bullet recovered. The gunshot wound of the right cheek and right hand could have been inflicted by a single bullet.

It is felt that the cause of death is regarded to be multiple gunshot wounds. The manner of death is ruled as homicide.

July 3, 2008
CSC/al

Chai S. Choi, M.D.

CHAI S. CHOI, M.D.

EXTERNAL EXAMINATION

AUTOPSY NO. ML 443-08

CASE NO. 0802189

| DESCRIPTION | | | | | | | | |
|---|--------|-------|---------------|---|-----------|-------|-----------|-------------|
| Height | Weight | Eyes | Pupils | Opacities, Etc. | hair | Beard | Mustache | Circumcised |
| 64 in. | 51 kg. | Brown | R 5 mm L 5 mm | | Lt. Brown | | | |
| RIGOR (jaw, neck, back, legs, arm, chest, abd., complete) | | | | LIVOR (color, anterior, posterior, lateral, regional) | | | Body Heat | |
| Complete | | | | Purple - Posterior | | | COOL | |

The body is that of a well developed, well nourished, white, female child. The conjunctivae are white and show no petechiae. There is blood in the nose and mouth, but not in the ear canals. There is blood stain over the face down to the neck. There are multiple gunshot wounds over the face which will be described below. Over the left submentum, there is entrance gunshot wound being surrounded by powder grain-like dark gray particles attached to the skin measuring approximately 8 x 10 cm over the left chin, lower cheek and down to the neck. The neck is unremarkable other than gunshot wound over the back of the neck which will be described below. The chest is of normal contour with unremarkable breasts. There is heart shape tattoo over the left breast region. The abdomen is flat and shows postmortem liver puncture mark over the right epigastrium. There are numerous letters and designs over the abdomen made by markers. The genitalia are those of a normal female of this age having short pubic hair. There is no traumatic injury in or around the genitalia. The extremities are symmetric and show elongated entrance gunshot wound over the left groin region which will be described. There is a through and through gunshot wound of the right hand with blood stains which will be described below. Both hands have been previously secured with brown paper bag sealed by plastic tape. There are small red-gray abrasions over the left knee and red abrasions over the left ankle and back of the left arm. There is blood spattering over the right shin. There is a somewhat V-shaped blue marker paint over the left shin and purplish-blue designs over the anterolateral surface of the left thigh by marker. There is somewhat Z-shaped paint over the left forearm and dorsum of the left hand painted by marker. There is yellow metal ring with cross around the left fourth finger. The back is unremarkable other than exit gunshot wound of the back of the neck at the mid-line and partial exit gunshot wound with bullet that is partly exposed located over the left upper back. There are similar words and designs made by markers over the lower back.

The decedent is clothed in the following:

- A t-shirt, light blue, "WORLD DISNEY, Junior 11/13, L" on the back with the inscription "MOOD SWINGS" on the front.
- Blue-purple underwear
- Red shorts with double white stripes on the sides, "ZOEY BETH, M"
- A pair of shoes, white, "NO BOUNDARIES, 6 ½"
- A "BETHING TOP", pink with flower patterns, "SAND SUN, L"

There are blood stains mainly over the front part of the t-shirt and left groin region of the shorts. There is blood spattering over the front part of the t-shirt and the front sleeve region. The back of the shirts are soaked with blood mainly on the upper part and right sleeve. There is a single ear piercing, bilateral. The toenails are stained with blue.

Evidence of injury:

- I. Entrance gunshot wound, left upper lip: Just below the left naris, there is a 0.5 cm entrance gunshot wound having elongated red peripheral abrasion rim at the lower margins measuring 0.5 x 0.8 cm. There is no soot blackening or powder stippling around the wound. The direction of the wound is backward, upward and slightly to the right, penetrating through the base of the tongue on the right, orbital bone at the mid-line, right orbital lobe, right caudate nucleus including basal ganglia, right parietal lobe at the superior surface near the mid-line. There is a markedly damaged copper coated lead bullet appearing to be small in size recovered in the brain matter. There is subarachnoid hemorrhages over the basal cisterns including pons.
- II. Entrance gunshot wound, left submentum: There is a 0.3 cm entrance gunshot wound having 0.2 cm red-brown peripheral abrasion rim being surrounded by powder grain described above and fine powder stippling around the wound that measures approximately 3 x 11 cm. There is no soot blackening identified. The direction of the wound is backward, slightly toward the right, fracturing the regional mandible on the left with vertical fracture and base of the skull. There is a small piece of lead is recovered at the subcutaneous tissue near the mid-line of the neck. There is a markedly damaged copper coated lead bullet, likely small in size recovered in the right side of the base of the skull. There is no exit gunshot wound present.

There is focal regional subdural hemorrhages of the cervical spine cord at the level of C-3 with periosteal contusion. The regional spinal cord is intact other than malacia.

- III. Entrance gunshot wound, right cheek: There is an irregular red-brown abraded laceration of gunshot wound measuring 0.7 x 1.3 cm being surrounded by oval shaped purple contusion rim measuring 3 x 3.5 cm. There is no soot blackening or powder stippling. The direction of the wound is backward, downward to the left perforating through the soft fibrofatty and musculature to the back of the neck just left of the mid-line. The regional sternomastoid muscle shows purplish contusive laceration. The exit wound measures 0.8 x 1 cm having irregular laceration at the margins. There is no soot blackening or powder stippling around the wound.
- IV. Entrance gunshot wound, left groin: There is 1.5 x 1.5 cm entrance gunshot wound having elongated red peripheral abrasion rim at the lower margins that measure 3 x between 0.5 and 1.5 cm. There is no soot blackening or powder stippling around the wound. The surrounding skin is bluish-purple and contused. The direction of the wound is backward, upward and slightly toward the right, penetrating through the left peritoneal muscle including psoas muscle, descending colon (x 1), small intestine (x 2), stomach, left hemispheric diaphragm, lower lobe of the left lung perivertebral region (T5), to the left back. There is a partial exit gunshot wound with partly exposed copper jacketed bullet appearing to be medium in size and is damaged. There is left hemothorax (approximately 500 mL of blood) with approximately 50 mL of hemothorax on the right and approximately 150 mL of blood in the peritoneum that is admixed with fecal material.
- V. Entrance gunshot wound, right hand: Over the third knuckle, there is a 2.1 x 1.5 cm entrance wound with a semicircular peripheral abrasion rim at upper margins and irregular lower and lateral margins. There is no soot blackening or powder stippling. There is no bullet recovered. There is a compound fracture of right third finger with multiple irregular lacerations over the volar surface of the finger

There are red abrasions and contusion over the right upper cheek and small red and gray and brown abrasions over the left knee, left ankle and back of the left arm described above. There is red horizontal linear scab over the left thigh.

GROSS EXAMINATION

AUTOPSY NO. ML 443-08

CASE NO. 0802189

The body is opened through the customary "Y" shaped incision.

Subcutaneous fat is normally distributed, moist, and bright yellow. The musculature through the chest and abdomen is rubbery, maroon, and shows no gross abnormality.

The sternum is removed in the customary fashion. The organs of the chest and abdomen are in normal position and relationship. The liver edge extends 0 cm below the right costal margin at the midclavicular line. The diaphragms is otherwise intact.

PARIETAL PLEURA:

Bilateral hemothorax described above.

PERICARDIUM:

Is a smooth, glistening, intact membrane, and the pericardial cavity, itself, contains the normal amount of clear, straw-colored fluid.

PERITONEUM:

Smooth, glistening membrane in both the abdominal and pelvic cavities. The peritoneal cavity contains approximately 150 mL of blood admixed with fecal material. There are left retroperitoneal hemorrhages and a psoas muscle contusive laceration.

HEART:

Weights 190 gm. It has a normal configuration and location. There are no adhesions between the parietal and visceral pericardium, and the latter is a smooth, glistening, fat laden characteristic membrane. The coronary arteries arise and distribute normally with no significant atherosclerosis. The coronary ostia are normally located and widely patent. The chambers and atrial appendages are unremarkable. The valves are normally formed and measure as follows: tricuspid 11 cm, pulmonic 5 cm, mitral 8 cm, and aortic 5.5 cm. The endocardium is a smooth and glistening with fine subendocardial hemorrhages. The myocardium is intact, flabby, and red-tan, with the left ventricle measuring 0.8 cm, the septum measuring 1 cm, and the right ventricle measuring 0.3 cm. The papillary muscles and chordae tendineae are intact and unremarkable. The arch of the aorta is classically formed with no atherosclerosis. Other great vessels also arise and distribute normally and are widely patent.

NECK ORGANS:

Musculature is normal, rubbery, and maroon, and the organs are freely movable in a midline position. The tongue is normally papillated and shows perforating gunshot wound with regional purplish hemorrhages at the base of the tongue on the right. The hyoid bone is intact. The thyroid cartilage is intact and without abnormality. The thyroid gland is symmetric, rubbery, pale, light brownish, and in its normal position without evidence of neoplasm. The epiglottis is a characteristic plate-like structure which shows no evidence of edema, trauma, or other gross pathology. The larynx is comprised of unremarkable vocal cords and folds, is widely patent without foreign material, and is lined by a smooth, glistening membrane. There are no petechiae of the epiglottis, laryngeal mucosa, or thyroid capsule.

THYMUS:

Pale and unremarkable.

LUNGS:

The right lung weighs 280 gm, and the left weighs 170 gm. Visceral pleurae are smooth and glistening other than through and through gunshot wound of the lower lobe of the left lung with regional hemorrhages. The overall configuration is normal. The trachea is filled with liquid blood. Likewise, the major bronchi and bronchioles bilaterally are normally formed, and contain bloody fluid. The pulmonary arterial tree is free of emboli or thrombi. The parenchyma is pale, pinkish-gray upper lobe and reddish-brown posterior segment of the lungs with numerous purple patches on the cut surfaces mainly on the left with a suggestion of aspiration of blood. There is a through and through gunshot wound of lower lobe of the left lung that measures 1 cm in greatest dimension each. It is located at the inferior surface of the lobe and close to the hilum. There is no evidence of granulomatous or neoplastic disease. Hilar lymph nodes are pale and unremarkable.

G.I. TRACT:

The esophagus shows an unremarkable mucosa, a patent lumen, and contains small amount of brownish fluid in the lumen. The esophagogastric junction is unremarkable. The stomach shows single perforated gunshot wound with focal regional hemorrhages at the posterior surface of the antrum measuring 2 cm and the anterior surface of the cardiac region of the stomach measuring 0.7 cm in greatest dimension. It contains a scanty amount of brownish mucoid material with no food. The duodenum, itself, is patent, shows an unremarkable mucosa and no evidence of acute or chronic ulceration. Jejunum and ileum are unremarkable other than two separate perforations by gunshot wound with focal regional hemorrhages. There is no Meckel's diverticulum. The ileocecal valve is intact and unremarkable. The appendix is unremarkable. The colon shows elongated perforation of the descending colon measuring 7.5 cm in greatest dimension. There are no diverticula. Anus and rectum are unremarkable.

LIVER:

Weighs 990 gm. It is of normal configuration, rubbery, somewhat pale brownish, and intact. Cut surface shows no pathology.

GALLBLADDER:

Lies in its usual position, contains liquid bile, no calculi, and shows a normal mucosa. The biliary tree is intact and patent without evidence of neoplasm or calculi.

PANCREAS:

Lies in its normal position, shows pancreatic hemorrhages at the distal one-third level.

SPLEEN:

Weighs 120 gm. The capsule is intact but wrinkled. The organ is rubbery, somewhat pale and brownish, and shows characteristic follicular pattern.

ADRENALS:

Pale and unremarkable.

KIDNEYS:

The right kidney weighs 90 gm and the left weighs 90 gm. Both are pale brownish. Sections show the organs to be moderately congested with unremarkable cortices, medullae and pelves. Ureters and blood vessels are patent and unremarkable.

URINARY BLADDER:

Contains a scanty amount of yellowish urine. Its serosa and mucosa are unremarkable.

FEMALE GENITALIA:

The vagina is intact and shows no gross pathology. The cervical os is with no erosion. The endocervical canal is within normal limits. The uterus has a symmetrical overall unremarkable configuration and is nongravid. The myometrium is light tan and rubbery. The endometrium is pale, light brown and measures approximately 0.6 cm in thickness. Bilateral adnexa are unremarkable other than ruptured corpus luteum of the right ovary.

BRAIN AND MENINGES:

The scalp is opened through the customary intermastoid incision and shows no trauma. The calvarium is removed through the use of an oscillating saw and is intact without evidence of osseous disease. The brain weighs 1400 gm. Dura and leptomeninges are smooth and glistening with subarachnoid hemorrhages mainly basal cisterns and orbital lobes and right parietal lobe at the superior surface. Cranial nerves and circle of Willis arise and distribute normally and show no significant pathology. Externally the brain is diffusely edematous and shows perforating gunshot wound through orbital lobe at the mid-line, right caudate nucleus, basal ganglia, right parietal lobe at the superior surface with regional hemorrhages through the tract. There is hemocephalus. There is a markedly damaged copper coated lead bullet appearing to the small in size recovered in the brain matter. The base of the skull is otherwise unremarkable.

RIBS:

Intact.

PELVIS:

Otherwise intact.

VERTEBRAE:

Otherwise intact.

BONE MARROW:

Moist and dark red. Unremarkable.

MICROSCOPIC EXAMINATION

AUTOPSY NO. ML 443-08

CASE NO. 0802189

Sections confirm the gross diagnosis and are otherwise unremarkable.

July 3, 2008
CSC/al

Chai S. Choi, M.D.

CHAI S. CHOI, M.D.

**BOARD OF MEDICOLEGAL INVESTIGATIONS
OFFICE OF THE CHIEF MEDICAL EXAMINER**

901 N.Stonewall
Oklahoma City, Oklahoma 73117

REPORT OF LABORATORY ANALYSIS

OFFICE USE ONLY

Re. _____ Co. _____

I hereby certify that this is a true
and correct copy of the original
document. Valid only when copy
bear im-print by the office seal.

By _____

Date _____

ME CASE NUMBER: 0802189

LABORATORY NUMBER: 082103

DECEDENT'S NAME: TAYLOR DAWN PASCHAL

DATE RECEIVED: 6/10/2008

MATERIAL SUBMITTED: BLOOD, VITREOUS, LIVER

HOLD STATUS: 30 DAYS

SUBMITTED BY: CHAI S. CHOI M.D.

MEDICAL EXAMINER: CHAI S. CHOI M.D.

NOTES:

ETHYL ALCOHOL:

Blood: NEGATIVE (HEART)

Vitreous:

Other:

CARBON MONOXIDE

Blood:


TESTS PERFORMED:

NO OTHER TESTS PERFORMED

RESULTS:

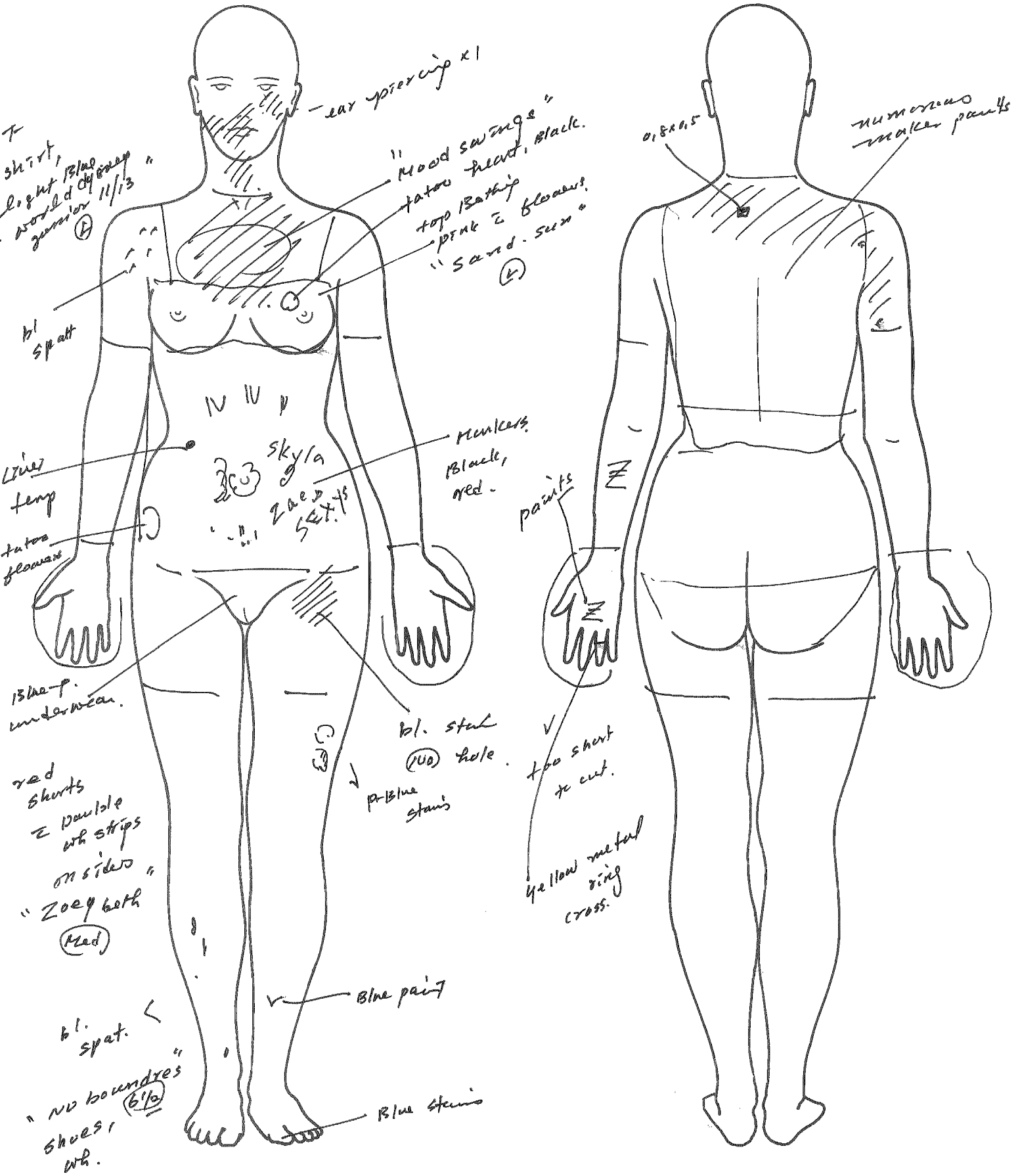
06/25/2008

DATE



BYRON CURTIS, Ph.D., Deputy Chief Forensic Toxicologist

FULL BODY, FEMALE - ANTERIOR AND POSTERIOR VIEWS

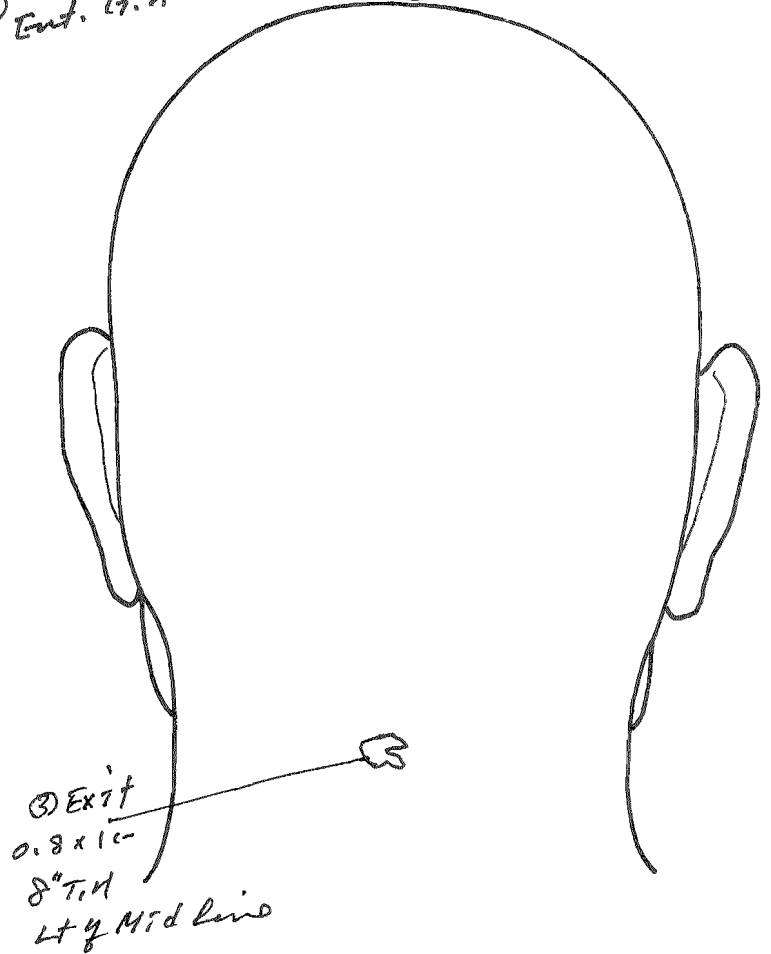
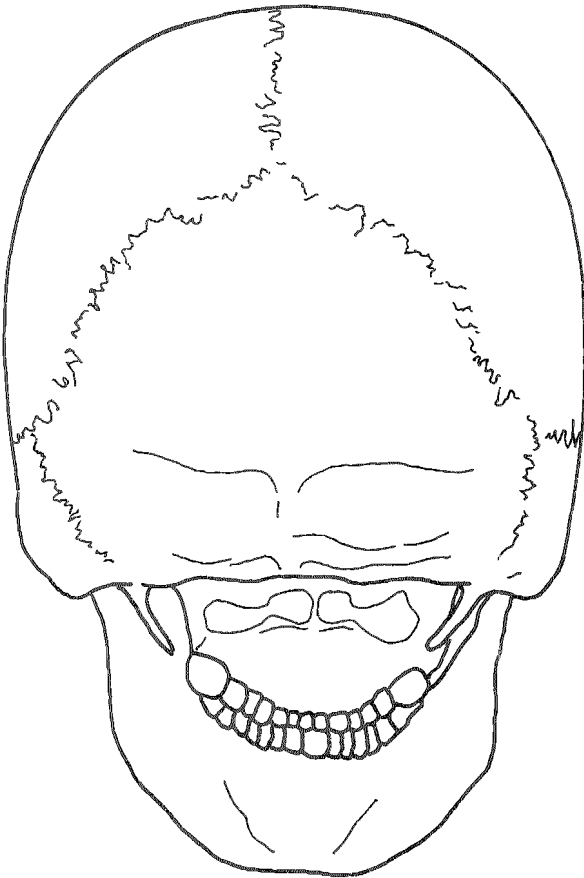
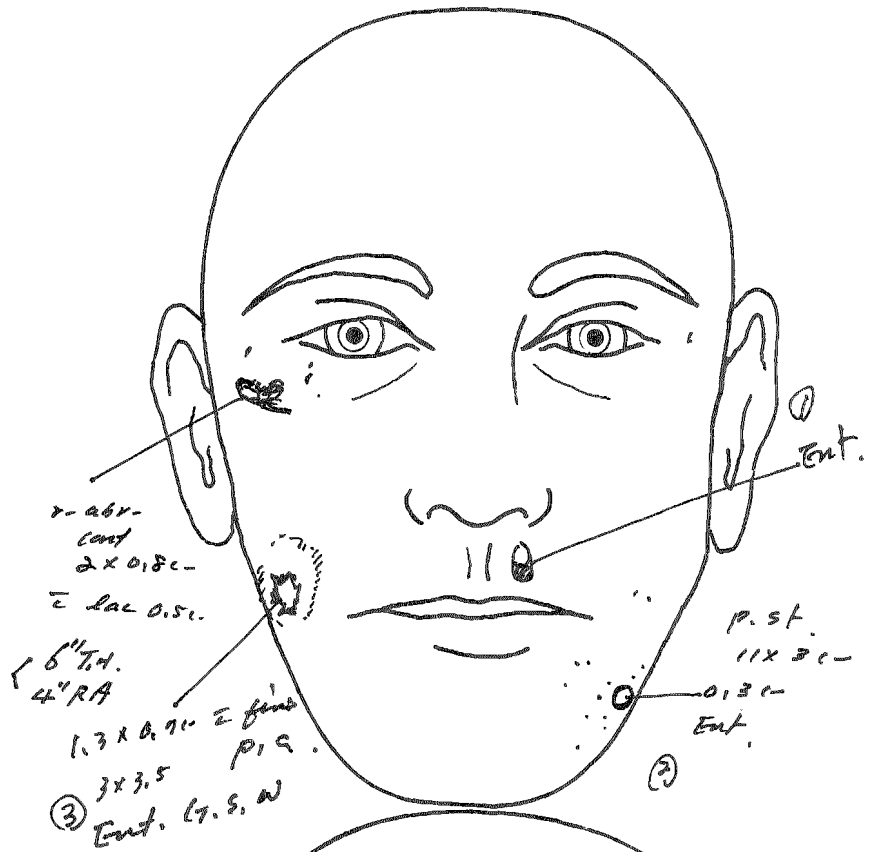
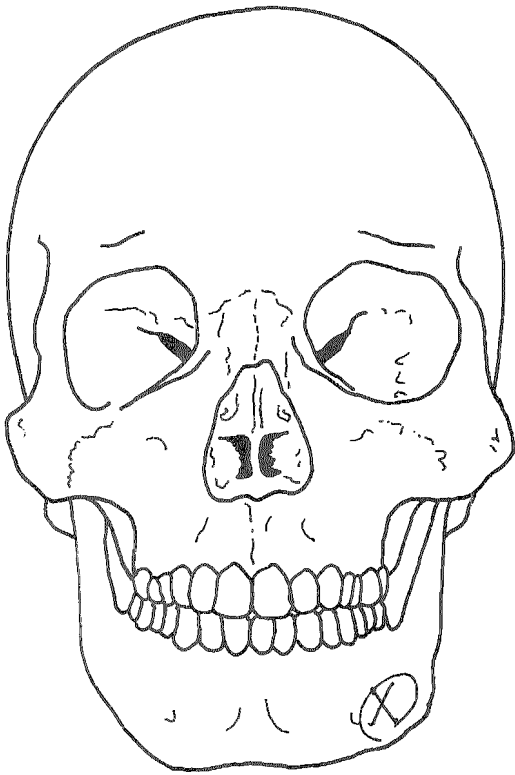


Name Taylor Dawn paschal

Case No. 0802189

Date 6-9-02

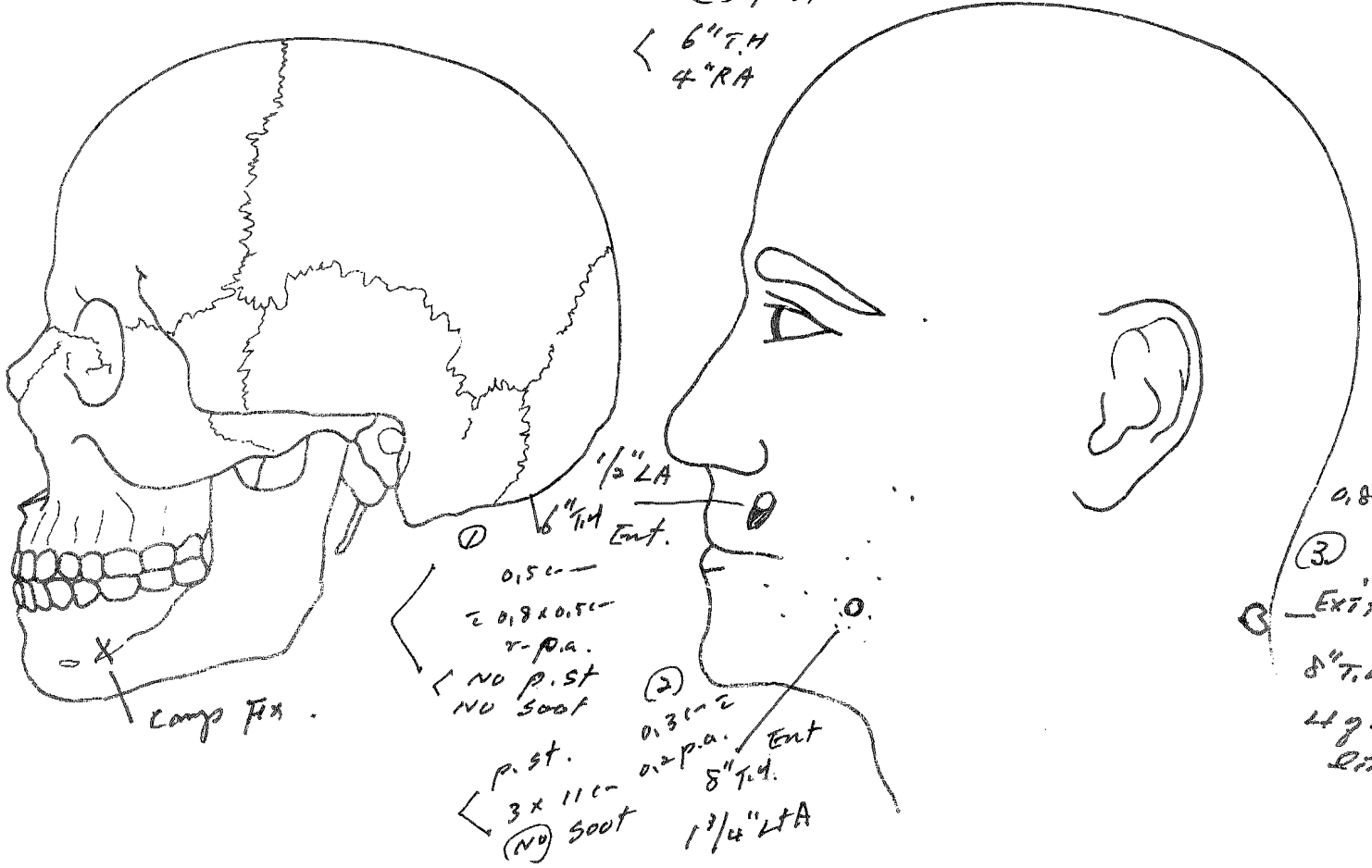
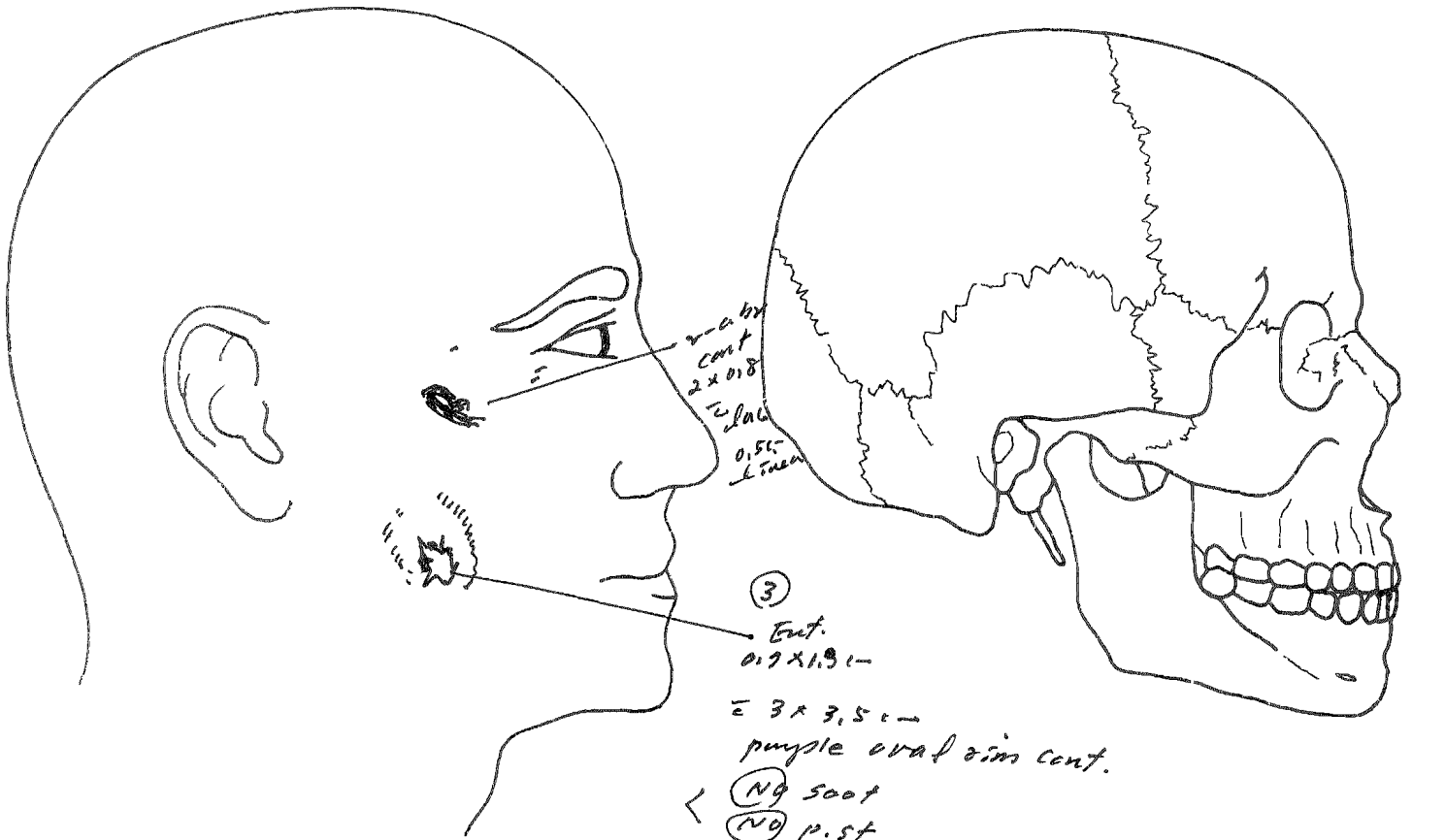
HEAD – SURFACE AND SKELETAL ANATOMY, ANTERIOR AND POSTERIOR VIEWS



Name Taylor Dawn paschal

Case No. 0202189

HEAD - SURFACE AND SKELETAL ANATOMY, LATERAL VIEW

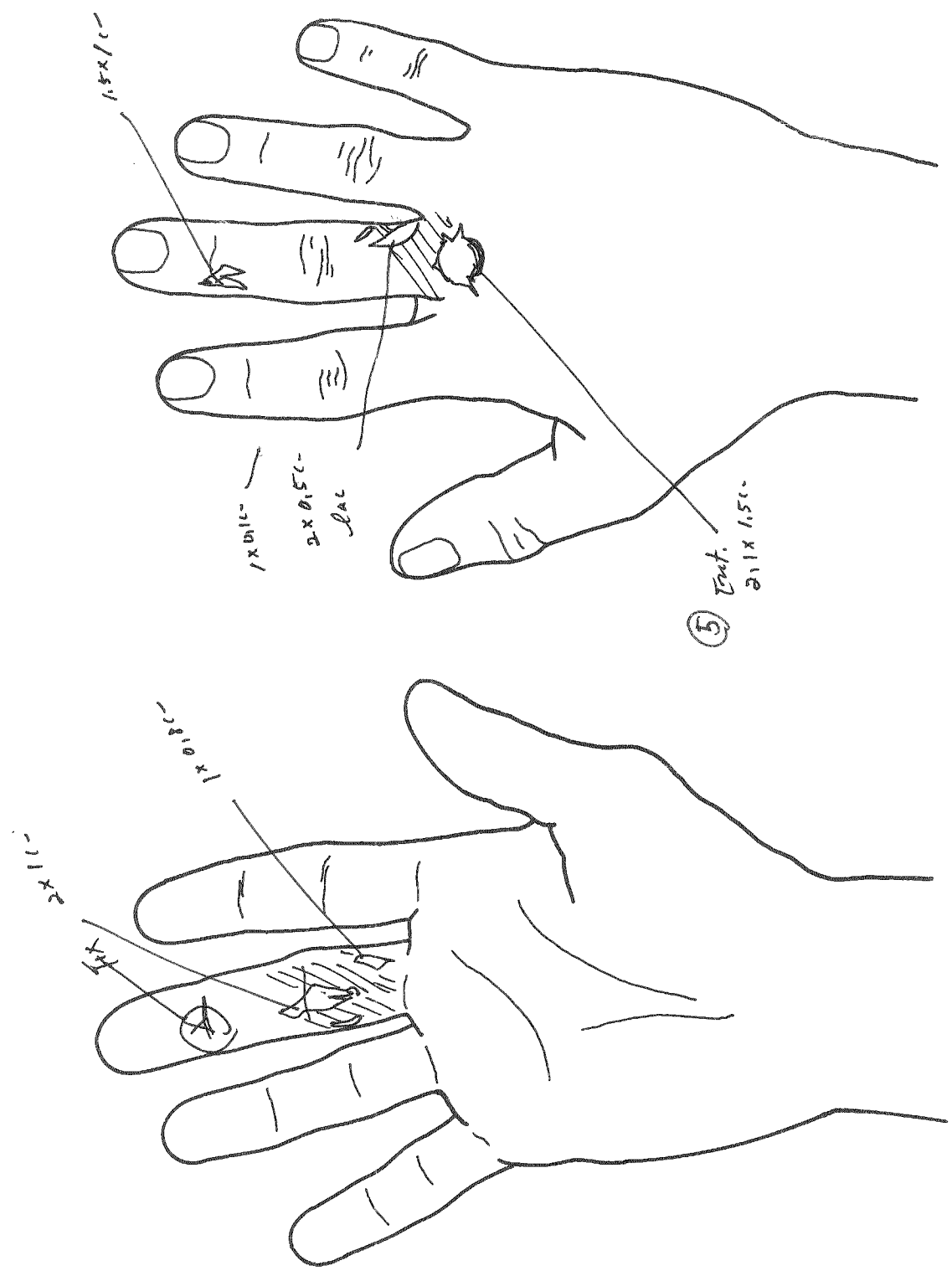


Name Taylor Dawn Paschal

Case No. 0802189

Date 6-9-10-08

RIGHT HAND - PALMAR AND DORSAL



Name Taylor Dawn paschal

Case No. 0802189

Date 6-9-10-08

GUNSHOT WOUND CHART

NAME Taylor Dawn Paschal A. No 0802189
 City or County _____

| | | WOUND NO. | | | | | | | | | | | |
|--------------------------------------|---|-----------------------|-----|--------------------|-----|-----------------------|-----|--------|-------|------|-------|------|-----|
| | | 1 | | 2 | | 3 | | 4 | | 5 | | 6 | |
| | | Ent. | Ex. | Ent. | Ex. | Ent. | Ex. | Ent. | Ex. | Ent. | Ex. | Ent. | Ex. |
| 1. Location of wound: | Head | ✓ | | ✓ | | ✓ | | | | | | | |
| | Neck | | | | | | | | | | | | |
| | Chest | | | | | | | | | | | | |
| | Abdomen | | | | | | | | | | | | |
| | Back | | | | | | | | ✓ | | | | |
| | Arm (Right) | | | | | | | | | | Hand. | | |
| | Left | | | | | | | | | | | | |
| | Right | | | | | | | | | | | | |
| | Leg (Left) | | | | | | | | Thigh | | | | |
| | 2. Size of wound: (Millimeters) <small>cm</small> | Diam. | 0.5 | | 0.3 | | | | | | | | |
| Width | | | | | | 0.7 | 0.8 | 1.5 | 0.8 | | | | |
| Length | | | | | | 1.3 | 1.0 | 1.5 | 2.0 | | | | |
| 3. Centimeters from wound to: | Top of head | 6 | | 8 | | 6 | 8 | 3 1/2 | 1 1/4 | | | | |
| | Right of midline | | | | | 4 | | | | | | | |
| | Left of midline | 1/2 | | 1 3/4 | | | 0 | 3 1/4 | Ⓟ | | | | |
| 4. Powder burns: | On skin | | | ✓ | | | | | | | | | |
| | Clothing | | | | | | | | | | | | |
| | Absent | ✓ | | | | ✓ | ✓ | ✓ | ✓ | ✓ | ✓ | | |
| 5. Direction of bullet through body: | Backward | ✓ | | ✓ | | ✓ | | ✓ | | | | | |
| | Forward | | | | | | | | | ✓ | | | |
| | Downward | | | | | ✓ | | | | ✓ | | | |
| | Upward | ✓ | | | | | | ✓ | | | | | |
| | To right | IL | | | | | | ✓ | | | | | |
| | To left | | | | | ✓ | | | | | | | |
| 6. Bullet found: | Calibre | damaged copper coated | | pieces by X-Ray | | damaged copper coated | | bullet | | | | | |
| | Shotgun | Calibre (B) (3) | | base & tongue (RT) | | Calibre (M) | | | | | | | |

Photographs made: Yes No X-rays made: Yes No

REMARKS: ①. Lt. upper lip - orbital bone (Mid) - Rt. orbital lobe, - Rt. caudate. - Rt. basal gailia - Rt. parietal lobe (sup. near midline) - (B).

②. Lt. Submentum - Comp. Frx of Mandible -

③. Rt. E. Neck - Back of Neck + cont of Neck m.)

Examined by: C. S. (Chai) Date: 6-9-10-08 -T5

stomach - Drash Lt - Lt Rev